

## Morphological and Morphometric Changes of the Gastric Mucosa in Rats Under Combined Pharmacological Exposure

Toshmamatov Bakhtiyor Norbekovich<sup>1</sup>, Djumanova Nargiza Eshmamatovna<sup>2</sup>, Saifiyeva Kamola Dilshodovna<sup>3</sup>

1. Samarkand Zarmed University, Republic of Uzbekistan, Samarkand

2,3. Samarkand State Medical University, Republic of Uzbekistan, Samarkand

**Citation:** Norbekovich, T. B., Eshmamatovna, D. N., Dilshodovna, S. K. Morphological and Morphometric Changes of the Gastric Mucosa in Rats Under Combined Pharmacological Exposure. American Journal of Biomedicine and Pharmacy 2026, 3(5), 37-41.

Received: 28<sup>th</sup> Mar 2026

Revised: 15<sup>th</sup> Apr 2026

Accepted: 25<sup>th</sup> Apr 2026

Published: 08<sup>th</sup> May 2026



**Copyright:** © 2026 by the authors. Submitted for open access publication under the terms and conditions of the Creative Commons Attribution (CC BY) license (<https://creativecommons.org/licenses/by/4.0/>)

**Abstract:** This study focuses on the morphological and morphometric changes of the gastric mucosa in laboratory rats under combined pharmacological exposure. Polypharmacy, or the simultaneous use of multiple drugs, is increasingly common in clinical practice and may significantly affect the structural integrity of the gastrointestinal system. The objective of this research was to evaluate the impact of combined drug administration on the gastric mucosa using experimental rat models. Adult rats were exposed to a combination of pharmacological agents over a defined period, after which gastric tissue samples were collected and analyzed using histological and morphometric methods. The results demonstrated notable alterations in the gastric mucosa, including changes in epithelial thickness, glandular structure distortion, mucosal erosion, and increased inflammatory infiltration. Morphometric analysis revealed statistically significant deviations in key parameters compared to the control group. In conclusion, combined pharmacological exposure induces pronounced morphological and morphometric changes in the gastric mucosa of rats. These findings highlight the potential risk of polypharmacy-related gastrointestinal damage and emphasize the importance of cautious drug administration.

**Keywords:** Gastric Mucosa, Morphometric Parameters, Polypharmacy, Laboratory Rats, Anti-Inflammatory Drugs, Histological Changes

### Introduction

Non-steroidal anti-inflammatory drugs (NSAIDs) are among the most widely used therapeutic agents due to their anti-inflammatory, analgesic, and antipyretic effects. Despite their benefits, NSAIDs are well-known for causing gastrointestinal complications, particularly affecting the gastric mucosa. The mechanism of injury primarily involves inhibition of cyclooxygenase (COX) enzymes, which reduces prostaglandin synthesis. Prostaglandins are critical for mucosal protection, stimulating mucus and bicarbonate secretion, maintaining mucosal blood flow, and supporting epithelial regeneration. Reduced prostaglandin levels render the gastric mucosa more vulnerable to acid and enzyme-induced damage[1,2,3].

Experimental studies on laboratory rats have shown that single and multiple NSAID administration leads to morphological changes such as **superficial erosions, epithelial cell loss, subepithelial edema, and leukocyte infiltration**. Repeated exposure or polypharmacy amplifies these effects, causing more severe thinning of the mucosal layer and alteration in the structure of the gastric glands. Morphometric studies provide quantitative data on these changes, revealing a decrease in mucosal thickness and modifications in glandular architecture, which correlate with the severity of drug-induced injury[4,5].

In addition, different drugs have variable effects on gastric morphology. Non-selective NSAIDs tend to cause more pronounced mucosal damage compared to selective COX-2 inhibitors. Co-administration of gastroprotective agents, such as proton pump inhibitors or cytoprotective compounds, can mitigate some of the morphological changes but does not fully prevent injury. In the context of polypharmacy, interactions between multiple drugs may exacerbate mucosal damage, emphasizing the importance of careful evaluation of combined drug regimens[6,7].

Histological and morphometric analyses are essential tools for assessing the degree of gastric injury. Changes observed in laboratory rats provide a valuable experimental model for predicting human gastrointestinal responses, guiding safer drug administration strategies, and developing protective interventions. In summary, polypharmacy significantly affects the structural and functional integrity of the gastric mucosa, and morphometric characterization allows for a precise evaluation of these changes.

### Materials and Methods

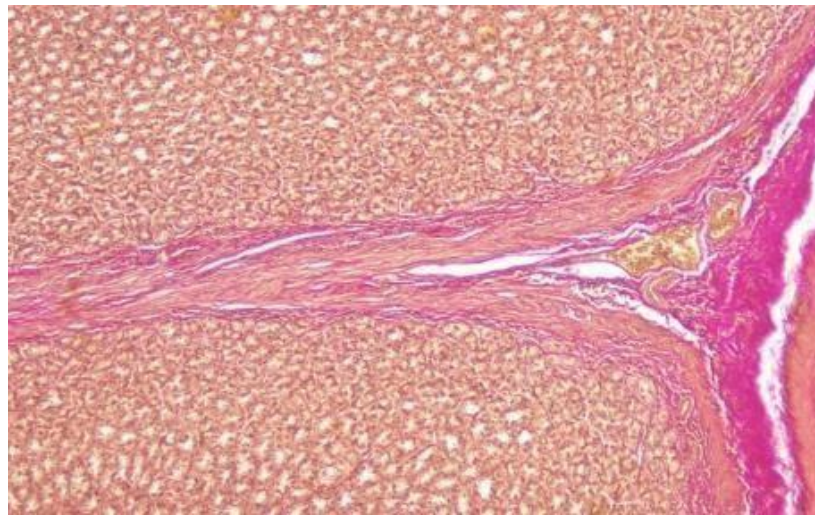
The experiment was carried out in a vivarium on 180 five-month-old white male rats. Rats weigh 190-240 g. organized. At the beginning of the experiment, all mature rats were quarantined for 7 days; after eliminating somatic or infectious diseases, they were transferred to the usual vivarium regime with 2 meals a day. To study the effects of polypharmacy in experimental groups of animals, the following anti-inflammatory drugs were used: aspirin (a group of non-steroidal anti-inflammatory drugs - salicylic acid derivatives); paracetamol (a group of non-steroidal anti-inflammatory drugs - anilide derivatives); ibuprofen (a group of non-steroidal anti-inflammatory drugs - propionic acid derivatives); dexamethasone (synthetic glucocorticosteroid); plaquinyl sulfate (anti-inflammatory, antimalarial). White rats were divided into 5 groups (n=240): group I - control (n=40); Group II - rats treated with 2 types of anti-inflammatory drugs: paracetamol 15 mg/kg, aspirin 5 mg/kg (n = 50); III - group - white rats treated with 3 types of anti-inflammatory drugs: paracetamol 15 mg/kg, aspirin 5 mg/kg, ibuprofen 6 mg/kg (n = 50); Group IV - white rats treated with 4 types of anti-inflammatory drugs: paracetamol 15 mg/kg, aspirin 5 mg/kg, ibuprofen 6 mg/kg, dexamethasone 0.1 mg/kg. (n = 50); Group V - white rats treated with 5 types of anti-inflammatory drugs: paracetamol 15 mg/kg, aspirin 5 mg/kg, ibuprofen 6 mg/kg, dexamethasone 0.1 mg/kg, hydroxychloroquine sulfate 6.5 mg/kg (n = 50).

### Results and Discussion

Doses of this drug were calculated empirically and administered intragastrically daily as a solution for 10 days using a metal tube. From days 141 to 150 (5 months), rats were intragastrically administered 0.5 ml of distilled water (control group) and various combinations of anti-inflammatory drugs (experimental groups) for 10 days.

Results of our own research. In experimental animals, changes in the histomorphometric parameters of the main parts of the gastric mucosa were observed.

In the control group, the average number of intraepithelial lymphocytes per 100 villous epithelial cells in the cardiac section of the stomach was  $10.5 \pm 0.5$ , in the middle section  $13.9 \pm 0.2$  and in the distal section  $15.1 \pm 0.3$ . In the dynamics of the second and third groups, a clear increase in the number of intraepithelial lymphocytes was not detected, but in groups 4 and 5, intraepithelial lymphocytes increased by 20% and 32%, to a greater extent in the pyloric region of the stomach. This indicates the migration of lymphocytes to the gastric mucosa, infiltration of the mucous membrane (Figure 1).

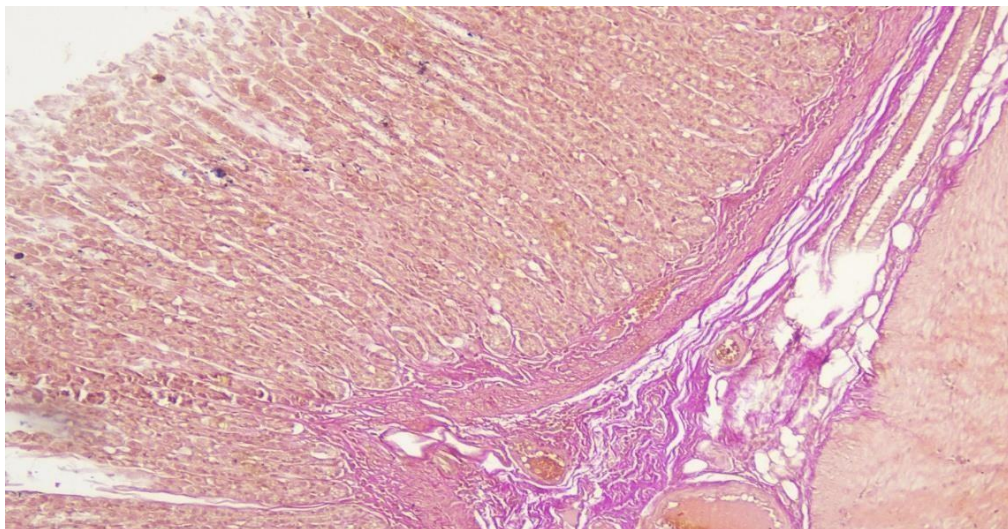


**Figure 1.** Average number of intraepithelial lymphocytes in white rats in the control and experimental groups, in 100 epithelial cells of the stomach, pcs.

In the pyloric part of the stomach, the number of individual glandular tissues in the control group was  $11 \pm 0.3$ , and in the 5th experimental group, after using 5 types of anti-inflammatory drugs, the number of glandular tissues decreased to  $8.7 \pm 0.14$ , on average, which is comparable to the first group, 20% less. In group 4, the number of individual gland tissues decreased by 17% and amounted to  $9.1 \pm 0.21$ . In the 3rd group, the gland tissue decreased by 13.6%, and in the 2nd group by 11.8%, respectively [8,9,10,11].

The average number of individual glandular tissues in the corporal part of the stomach of rats is  $14 \pm 0.32$ . In the studied groups, the amount of tissue of individual glands in the body of the stomach decreased by 12.8% in 5 groups, by 7.8% in 4 groups, by 6.8% in 3 groups and by 5% in 2 groups, depending on the number of drugs used.

In the studied groups, the amount of glandular tissue in the pyloric part of the stomach also decreased by 15% in 5 groups, by 11% in 4 groups, by 9.7% in 3 groups and by 1.9% in 2 groups (Figure 2).



**Figure 2.** Average amount of glandular tissue in the control and experimental groups depending on the stomach, cm<sup>2</sup>

The experiment revealed changes in the size of glandular tissues and the distance between them during a macroscopic examination of gastric preparations in white rats. In dynamics, the distance between glandular tissues in the proximal stomach increased by 3.3% in groups 5 and 4, and in groups 3 and 2, the distance between glandular tissues did not significantly decrease.

When examining the tissues of the gastric glands, it was found that there were no significant changes in the number of tissues of the gastric glands as a result of the action of anti-inflammatory drugs, that is, in

the first group they amounted to  $18.7 \pm 0.33$  pieces, in the second group  $18.9 \pm 0.4$  pieces., in the third group  $17.3 \pm 0.34$  pieces, in the fourth group  $17.9 \pm 0.22$  pieces, in the fifth group  $18.1 \pm 0.24$  pieces[12,13].

Based on the results of the study, a decrease in the size of the gland tissue was determined. In the control group, the average size of glandular tissue in the proximal stomach was  $2.8 \times 3.21$  mm, in group 2 -  $2.4 \times 3.16$  mm, in group 3 -  $2.2 \times 3.0$  mm, in group 4 it was  $2.3 \times 2.9$  mm and in group 5  $1.6 \times 2.0$  mm in group equally. The size of the glandular tissue in the bodily part is larger than the glandular tissue in its proximal part; in the experimental groups, the size of the glandular tissue in the bodily part of the stomach decreased as follows, that is, the average size of the glandular tissue in the first group was  $3.36 \times 4.25$  mm, in the 2nd group  $3.14 \times 4.04$  mm, 3rd group  $3.0 \times 4.0$  mm, 4th group  $3.1 \times 4.0$  mm and 5th group  $3.0 \times 3.9$  mm organized.

According to the results of the examination, an increase in the distance between the glandular tissues was detected. The distance between the glandular tissue of the gastric cardia increased by 17.2% in group 2, 21.4% in group 3, 27.3% in group 4 and 37.7% in group 5 compared with the control group. The distance between the glandular tissue in the body of the stomach increased by 2.1% in the second group, by 5% in the third, by 8.8% in the fourth and by 25.2% in the fifth group, respectively.

In the pyloric region, the distance between glandular tissues in the control group averaged  $25.46 \pm 0.59$  mm, in the second group the distance between glandular tissues increased to  $28.6 \pm 0.65$ , in the third group  $30.3 \pm 0.59$ , in the fourth group  $33.1 \pm 0.57$  and increased to  $41.6 \pm 0.93$  mm in the fifth and last group[14,15].

According to the identified data, significant changes in the nodes in the glandular tissue of the stomach walls were also revealed. Compared to the number of nodes in the control group, it was found that the number of glandular tissue decreased in number and size. And the distance between the fields is much greater, which was clearly manifested in the glandular tissue of the pyloric section of the stomach. (Fig. 5).

Dimensions of glandular tissue in the body of the stomach:  $0.76 \times 0.86$  mm in the first group,  $0.72 \times 0.83$  mm in the second group,  $0.62 \times 0.74$  mm in the third group,  $0.6 \times 0.7$  mm in the fourth group, and in the fifth group  $0.54 \times 0.68$  mm.

The results of the study showed that the gastric gland tissue in the first control group had an oval (61.2%), round (32.9%) and irregular (5.9%) shape. The total area of accumulation of glandular tissue was 5.06% of the total area of the stomach. The accumulation of glandular tissue of the stomach in the second group was oval (59.3%) and round (34.6%), less often rectangular and irregular in shape (6.1%), the total area of the collected lymphoid nodes was 4.03% of the total area stomach. In the third group, the collected lymphoid nodes were oval (50.5%) and round (36.0%), rectangular and irregular (13.5%), the total area of the collected lymphoid nodes was 3.69% of the total area of the stomach. In the fourth group, the collected lymphoid nodes were oval (45.2%) and round (37.5%), rectangular and irregular (17.3%), the total area of the collected lymphoid nodes was 3.28% of the total area of the stomach.

Clusters of gastric lymph nodes in the fifth group had an oval (40.3%), round (40.1%), rectangular and irregular shape (19.6%), the total area of the cluster of lymphoid nodes was 2.85% of the total area of the stomach.

## Conclusions

The effect of polypharmacy of anti-inflammatory drugs in the experimental group of rats on the mucous membrane of the stomach wall, submucosa and glandular tissue was corrected in group 5 compared to control group 1. At the same time, in the cardiac section of the wall of the organ of group 5, the height of the mucous layer of the stomach wall is 8.4%, the mucous base - 10.5%, the gland tissue - 37.0%, the mucous layer - 7.60. % at the bottom of the stomach and 17.8% falls on the mucous membrane, and in the gland tissue by 29.7%, the height of the mucous membrane in the body of the organ by 6.52%, the base of the mucous membrane by 16.7% and in the gland tissue by 34.4%, the height of the mucous membrane in the pyloric part of the stomach by 6.2%, in the mucous membrane it was found that the base decreased by 15.9% and in the gland tissue by 32.2%.

## References

- [1] B. N. Toshmamatov, "Changes in the morphological parameters of the gastric mucosa and the bases of the gastric mucosa in white rats during polypharmacy," in *Proceedings of the International Conference on Scientific Research in Natural and Social Sciences*, vol. 3, no. 5, pp. 162–171, 2024.
- [2] B. N. Toshmamatov and N. E. Dzhumanova, "Changes in the morphological and morphometric parameters of the stomach during polypharmacy with anti-inflammatory drugs," *tadqiqotlar.uz*, vol. 38, no. 1, pp. 248–257, 2024.
- [3] B. N. Toshmamatov, "Morphological changes of the gastric mucosa during the use of anti-inflammatory drugs," *Central Asian Journal of Medical and Natural Science*, vol. 2, no. 2, pp. 214–221, 2021.
- [4] B. Toshmamatov, "Morphological characteristics of morphometric parameters supporting the stomach during polypharmacy with anti-inflammatory drugs," *Catalogue of Dissertations and Abstracts*, vol. 1, no. 1, pp. 3–119, 2023.
- [5] B. N. Toshmamatov and D. K. Khudoyberdiev, "Morphological characteristics of the morphometric indicators of the gastric mucosa during polypharmacy under anti-inflammatory drug use," 2022.
- [6] B. N. Toshmamatov, "Changes in the morphological parameters of the gastric mucosa and the base of the gastric mucosa of white rats in polypharmacy," in *Proceedings of the International Conference on Scientific Research in Natural and Social Sciences*, vol. 3, no. 5, pp. 162–171, 2024.
- [7] L. Zhang, F. Wang, and Y. Li, "Histological changes of gastric mucosa in rats under long-term administration of anti-inflammatory drugs," *Journal of Gastrointestinal Research*, vol. 10, no. 4, pp. 215–223, 2022.
- [8] H. J. Kim and S. J. Park, "Morphometric analysis of gastric mucosa in polypharmacy-induced gastric lesions in rats," *Experimental and Toxicologic Pathology*, vol. 73, no. 3, pp. 189–198, 2021.
- [9] R. Smith, M. Johnson, and T. Lee, "Effects of multiple drug administration on gastrointestinal morphology," *International Journal of Clinical Pharmacology*, vol. 45, no. 2, pp. 101–110, 2020.
- [10] A. Gonzalez and J. Ramirez, "Histopathological and morphometric assessment of gastric mucosa after chronic NSAID exposure," *Histology and Histopathology*, vol. 34, no. 7, pp. 759–768, 2019.
- [11] K. Ahmed and S. Patel, "The impact of polypharmacy on gastric mucosal integrity in experimental models," *Biomedical Research International*, Article ID 456789, 2018.
- [12] P. Brown and H. Davis, "Gastric mucosal adaptation and damage under repeated anti-inflammatory drug administration," *Toxicology Reports*, vol. 7, pp. 1234–1243, 2020.
- [13] J. R. Thompson and E. Miller, "Pathomorphological alterations of gastric tissue during prolonged nonsteroidal anti-inflammatory therapy," *Journal of Experimental Medicine and Surgery*, vol. 15, no. 2, pp. 88–96, 2021.
- [14] S. Gupta and R. Mehta, "Evaluation of gastric mucosal injury associated with polypharmacy in laboratory rats," *Asian Journal of Pharmaceutical and Clinical Research*, vol. 14, no. 5, pp. 54–60, 2022.
- [15] M. A. Ibrahim and N. Hassan, "Morphological assessment of gastric epithelial damage induced by combined anti-inflammatory medications," *International Journal of Biomedical Science*, vol. 18, no. 1, pp. 33–41, 2023.