American Journal of Biomedicine and Pharmacy
https://biojournals.us/index.php/AJBP
ISSN: 2997-7177

Clinical and Dermoscopic Evaluation of Melasma: A Study of Patterns, Severity, and Associated Risk Factors

Ali Jafar Mohammad[1], Nadia H. Sahib[2], Fatin Ahmed Fakhry[3], Mohammed Abbas Mohammed[4], Mohammed Sameir*[5]
1,2,3,4,5. Hammurabi College of Medicine, University of Babylon, Iraq
*Correspondance: ham767.mohammed.sameir@uobabylon.edu.iq

Citation: Mohammad, A. J., Sahib, N. H., Fakhry, F. A., Mohammed, M. A., Samier, M. Clinical and Dermoscopic Evaluation of Melasma: A Study of Patterns, Severity, and Associated Risk Factors. American Journal of Biomedicine and Pharmacy 2026, 3(5), 163-170.

Received: 28th Mar 2026
Revised: 15th Apr 2026
Accepted: 05th May 2026
Published: 30th May 2026

Copyright: © 2026 by the authors. Submitted for open access publication under the terms and conditions of the Creative Commons Attribution (CC BY) license (https://creativecommons.org/licenses/by/4.0/)

Abstract: Melasma is a common acquired hyperpigmentary disorder characterised by symmetrical brown macules and patches affecting mainly sun-exposed facial areas. Melasma predominantly affects women of reproductive age and is associated with several contributing factors, including ultraviolet radiation, hormonal changes, pregnancy, oral contraceptive use, and genetic susceptibility. Dermoscopy is increasingly used as a non-invasive method to examine pigment depth, vascular alterations, and features that may provide prognostic information. The aim of this study was to describe the clinical and dermoscopic features of melasma, to evaluate the severity of the disease with Melasma Area and Severity Index (MASI) and to evaluate the correlation between dermoscopic findings and major clinical risk factors. In this study, a total of 80 patients with clinical diagnosis of facial melasma attending the dermatology outpatient clinic were included. Demographic and clinical characteristics were collected, including age, sex, skin phototype, family history, use of oral contraceptives, topical steroids, sun exposure and history of melasma during pregnancy. Patterns were classified clinically according to the distribution of facial pigmentation. Dermoscopic evaluation was performed using a handheld dermoscope at ×10 magnification and disease severity was assessed using MASI scores. The mean age of the participants was 34.5 ± 5.2 years, with women accounting for 95.0% of the study population. Malar involvement was the most common clinical presentation, observed in 72.5% of patients. On dermoscopic examination, brown globules and dots were the most frequently observed features (97.5%), followed by brown background pigmentation (90.0%) and an irregular pigment network (87.5%). Telangiectasia was also identified in 77.5% of patients. A significant association was found between sun exposure and telangiectasia (OR = 4.67; 95% CI: 1.28–16.99; p = 0.023). Overall, dermoscopy offers useful clinical information for evaluating melasma, particularly in identifying pigmentation patterns and vascular changes. These findings may help support clinical assessment and guide individualized management.

Keywords: Melasma, Dermoscopy, Hyperpigmentation, Telangiectasia, Sun Exposure

Introduction

Melasma is an acquired pigmentary condition characterised by symmetrical light-to-dark brown macules and patches, typically appearing on sun-exposed areas of the face, including the cheeks, forehead, upper lip, nose, and chin [1], [2]. It is a common dermatological condition associated with pigmentary complaints and can cause significant psychological distress and cosmetic concern especially in women of reproductive age [1], [3]. Melasma is more common in individuals with Fitzpatrick skin phototypes III–V, particularly those living in areas of high ultraviolet (UV) radiation, such as the Middle East, South Asia, and Latin America, although individuals of many ethnicities can develop melasma [1], [4].

There is not one underlying cause for melasma, but a complicated interaction of factors. Genetic predisposition, UV radiation, visible light, hormonal changes, pregnancy, oral contraceptive use, thyroid

dysfunction, inflammation and exposure to certain cosmetic or pharmacologic agents have been implicated in the pathogenesis of this condition [2], [5]. Solar radiation is a very important factor which initiates and worsens pigmentation. UV radiation exposure stimulates melanocyte activity and increases melanin synthesis and also changes the interactions between epidermis and dermis which contributes to excessive pigmentation [1], [2]. Other identified changes include vascular changes, basement membrane injury, mast cell activation, oxidative stress and fibroblast senescence and low-grade chronic inflammation. These processes suggest that melasma is not restricted to hyperactive melanocytes, and can be regarded as a photoaging-related skin disease [6, 2].

Melasma is usually classified into three clinical patterns based on the distribution of facial lesions: centrofacial, malar and mandibular. The centrofacial pattern is reported to be the most frequent among these [3]. The condition can also be classified according to depth of melanin deposition into epidermal, dermal and mixed types. Histopathological or Wood's lamp examination usually establishes this distinction which may influence treatment response and prognosis [1], [7]. Wood's lamp examination results, however, are not always reliable, especially in people with darker skin phototypes. Conversely, a histopathological assessment is not routinely performed due to its invasive nature and limited feasibility in daily clinical practice [5].

Recently, dermoscopy has become more advantageous in evaluation of pigmentary skin disorders. This non-invasive technique provides clinicians with a more complete assessment of pigment distribution, vascular structures, and perifollicular changes than can be achieved by conventional visual inspection alone [8]. Dermoscopy can be useful in identifying pigmentation and differentiating features suggestive of epidermal or dermal involvement in melasma patients. The most frequent reported findings are diffuse reticuloglobular brown pigmentation, irregular pigment networks, arcuate structures, telangiectasia and perifollicular sparing [8], [9]. In addition to its diagnostic value, dermoscopy may also be helpful in clinical decision-making. For example, the identification of vascular and mixed pigmentary features may be helpful in assessing the potential for treatment resistance and response to treatment [9, 10].

Evaluating the severity of melasma is another important aspect of patient assessment and clinical research. The Melasma Area and Severity Index (MASI) is widely used to measure disease severity based on the extent of affected facial areas and the characteristics of pigmentation [7]. Combining MASI assessment with dermoscopic examination may offer a broader perspective on disease characteristics, particularly when investigating whether specific dermoscopic patterns correspond to greater clinical severity. Such an approach could also contribute to a more individualised assessment and management of affected patients.

The increasing use of dermoscopy in dermatological practice has not been followed by evidence regarding the correlation between the dermoscopic characteristics, clinical severity, and associated demographic and clinical risk factors in patients with melasma. This is especially true for regional populations, where hormonal influences and environmental exposures may differ. The present study aimed to evaluate the clinical and dermoscopic characteristics of melasma, to identify the main dermoscopic patterns, to evaluate the severity of the disease using MASI and to investigate their correlations with relevant demographic and clinical risk factors.

Materials And Methods

Study design and patients

The aim of this cross-sectional clinical observational study was to assess the clinical and dermoscopic features of patients diagnosed with melasma, and to correlate these features with disease severity and relevant demographic and risk factors. During the course of the investigation, eighty patients with clinically diagnosed melasma were consecutively enrolled. The diagnosis of melasma was made based on the characteristic clinical presentation of bilateral hyperpigmented macules and patches on sun-exposed areas of the face, and supported by dermatological examination. Rephrase sentence Revert to original sentence Copy sentence Synonyms by through from for via due to with in as because of within at using according to out of throughout among thanks to to of based on as a result of on upon by during caused by primarily by with regard to on behalf of around between.

Inclusion and exclusion criteria

Patients with clinical diagnosis of facial melasma were included in the study. Patients with other facial pigmentary disorders that could interfere with diagnosis, such as post-inflammatory hyperpigmentation, lichen planus pigmentosus, exogenous ochronosis, or drug-induced pigmentation and patients with history of recent facial chemical peeling, laser therapy, or depigmenting procedures within the previous 3 months were excluded from the study.

Data collection

A detailed clinical history was obtained from all participants using a structured questionnaire. Demographic variables included age, sex, occupation, marital status, and Fitzpatrick skin phototype. Clinical variables included duration of melasma, age at onset, family history, history of pregnancy-related melasma, use of oral contraceptive pills, thyroid disease, cosmetic use, sun exposure, sunscreen use, and history of previous treatment. Clinical examination included documentation of the anatomical distribution pattern of melasma, classified as centrofacial, malar, or mandibular type according to standard clinical classification. The pattern and extent of pigmentation were recorded by consultant dermatologists.

Assessment of disease severity

The Melasma Area and Severity Index (MASI) was used to evaluate the severity of melasma and is still one of the most accepted clinical scoring systems for evaluation of melasma [2]. MASI scoring was done by evaluating four facial regions i.e. forehead (30%), right malar region (30%), left malar region (30%) and chin (10%). For each facial region, three factors were assessed: homogeneity of pigmentation (H), area affected (A), and darkness of pigmentation (D). These parameters were calculated for total MASI score. The severity of the disease was then classified as mild, moderate or severe melasma according to the scoring ranges determined in previous studies.

Dermoscopic examination

Dermoscopic examinations were conducted using a handheld dermoscope (DermLite DL4, 3Gen Inc., USA) at ×10 magnification under standardised lighting conditions. Polarised and non-polarised modes were selected as appropriate during the assessment.

The following dermoscopic features were specifically evaluated:

1. Pigment network pattern
2. Reticuloglobular pigmentation
3. Arcuate and annular structures
4. Perifollicular sparing
5. Telangiectasia
6. Vascular components
7. Brown, grey, or bluish pigmentation
8. Epidermal, dermal, or mixed pigment pattern

Dermoscopic classification was performed according to previously validated criteria described in the literature. The dermoscopic images of representatives were recorded for analysis and comparison.

Statistical analysis

Statistical analysis was conducted using the Statistical Package for the Social Sciences (SPSS), version 26. Continuous data were summarised as mean ± standard deviation (SD), whereas categorical data were reported as frequencies and percentages.

The relationships between dermoscopic findings and clinical variables were examined using the Chi-square test for categorical data and one-way analysis of variance (ANOVA) for continuous data, where appropriate. Pearson's correlation coefficient was also used to evaluate the relationship between MASI scores and dermoscopic features, depending on the distribution of the data.

Statistical significance was defined as a p-value of less than 0.05.

Ethical Considerations

All participants gave written informed consent prior to their enrolment. The study was performed in accordance with the ethical principles of the Declaration of Helsinki and confidentiality of patient data was strictly preserved. Ethical approval was granted by the Institutional Research Ethics Committee at [insert institution name] with approval number [insert approval number].

Results

This cross sectional study was carried out on 80 patients clinically diagnosed as melasma. Participants had a mean age of 34.5 ± 5.2 years, with ages ranging from 25 to 46 years. Females comprised 95.0% of the study cohort and males only 5.0% of the occurrences. This distribution reflects the predominance of melasma among the female subjects of the study population.

Fitzpatrick skin phototype III was slightly more common than type IV, accounting for 55.0% and 45.0% of patients, respectively. The most frequent clinical distribution pattern was malar melasma (72.5%), followed by centrofacial (7.5%), mandibular (7.5%), combined malar–centrofacial (7.5%), and malar–mandibular involvement (5.0%).

Regarding disease duration, the majority of patients had melasma for 2–4 years, with 3 years being the most common duration (32.5%). Positive family history was reported in 15.0% of cases. History of oral contraceptive pill use was present in 27.5%, while topical corticosteroid use was observed in 75.0% of patients. Significant sun exposure was reported by 85.0% of participants, and pregnancy-induced melasma was documented in 50.0% of female patients (Tab. 1).

Table 1. The Demographic and clinical characteristics of the study population

Variable	Frequency (n=80)	Percentage (%)
Sex		
Female	76	95.0
Male	4	5.0
Skin type		
Type III	44	55.0
Type IV	36	45.0
Clinical site		
Malar	58	72.5
Centrofacial	6	7.5
Mandibular	6	7.5
Malar + Centrofacial	6	7.5
Malar + Mandibular	4	5.0
Family history		
Yes	12	15.0
No	68	85.0
Drug history (OCP use)		
Yes	22	27.5
No	58	72.5
Topical steroid use		
Yes	60	75.0
No	20	25.0
Sun Exposure		
Yes	68	85.0
No	12	15.0
Pregnancy-induced melasma		
Yes	40	50.0
No	40	50.0

Dermoscopic findings

Brown background pigmentation was the predominant dermoscopic finding, observed in 90.0% of patients, while mixed pigmentation was seen in 7.5% and blue-grey pigmentation in only 2.5%. The most common dermoscopic pattern was irregular pigment network (87.5%). Regular network was seen only in 12.5% of patients.

Epidermal pigmentation patterns were predominant, with brown globules and dots present in 97.5% of the patients. Telangiectasia was found in 77.5% of cases (Tab. 2), suggesting a significant vascular component associated with the melasma lesions.

Table 2. The Dermoscopic characteristics of melasma

Variable	Frequency (n=80)	Percentage (%)
Background pigmentation		
Brown	72	90.0
Mixed	6	7.5
Blue-grey	2	2.5
Dermoscopic pattern		
Irregular network	70	87.5
Regular network	10	12.5
Globules and dots		
Brown	78	97.5
Mixed	2	2.5
Telangiectasia		
Present	62	77.5
Absent	18	22.5

Association between clinical factors and telangiectasia

A statistically significant association was observed between sun exposure and the presence of telangiectasia. Patients with significant sun exposure were more likely to have telangiectatic changes than those without significant sun exposure (OR = 4.67; 95 % CI: 1.28–16.99; p = 0.023). Topical corticosteroid use also showed an increased odds ratio for telangiectasia (OR = 3.33; 95% CI: 1.08–10.25), although the association did not reach conventional statistical significance (p = 0.060). There were no statistically significant associations between telangiectasia and family history, oral contraceptive use, pregnancy-induced melasma or skin phototype (p <0.05).

Table 3. Association of telangiectasia with selected risk factors

Variable	Odds Ratio (OR)	95% CI	p-value	Significance
Sun exposure	4.67	1.28–16.99	0.023	Significant
Topical steroid use	3.33	1.08–10.25	0.060	Borderline
Family history	0.52	0.14–1.97	0.452	Not significant
OCP use	0.70	0.22–2.16	0.557	Not significant
Pregnancy-induced melasma	0.75	0.26–2.15	0.790	Not significant
Skin type IV vs III	1.88	0.62–5.63	0.294	Not significant

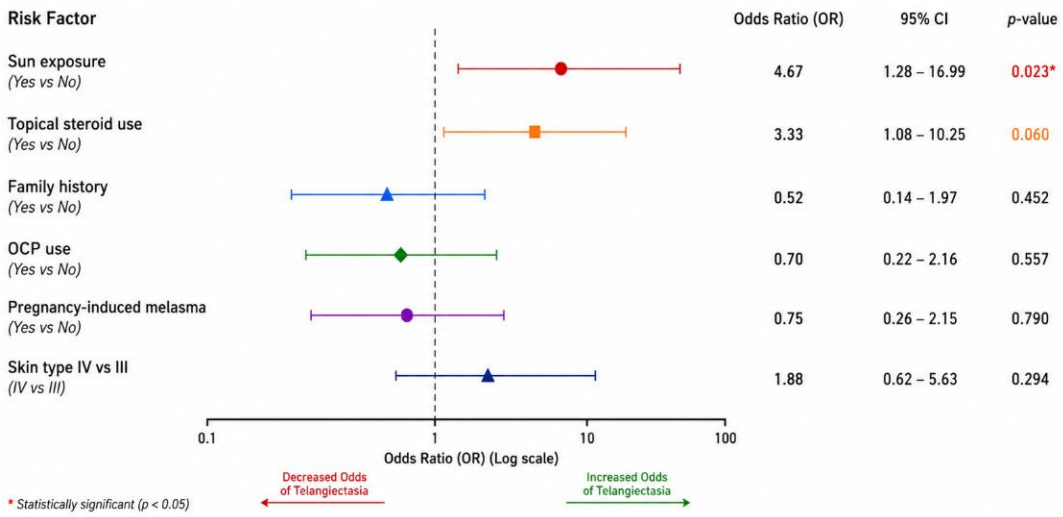

Figure 1. The forest plot illustrates the relationship between telangiectasia in patients with melasma and the presence of major clinical risk factors.

The forest plot shows that sun exposure was the strongest statistically significant predictor of telangiectatic dermoscopic changes, whereas the use of topical steroids was clinically relevant but borderline significant.

Discussion

The chronicity and recurrence of melasma, along with its significant psychosocial impact, continue to be a therapeutic challenge in dermatology practice. Objective to study the clinical and dermoscopic features of melasma with special emphasis on the correlation of clinical risk factors with the dermoscopic findings. The findings revealed a significant association between telangiectasia and exposure to the sun. It implies that vascular alterations could be a key characteristic of the disease. These findings add to the emerging evidence that melasma is the outcome of multiple interacting pathogenic mechanisms and that dermoscopy can provide useful information in routine clinical assessments.

The mean age of patients in this study was 34.5 ± 5.2 years. The percentage of women in this study was 95.0%. This distribution is in line with previous studies which have invariably shown that melasma is more common in women of reproductive age. Hormonal factors, especially oestrogen and progesterone, are believed to be significant contributors because of their influence on melanogenesis and the responsiveness of melanocytes to ultraviolet radiation [11], [12]. Handel et al. also reported that the majority of patients were female and the highest incidence was in the third and fourth decades of life [1]. The age and sex distribution observed in the present study was concordant with the demographic pattern that is generally described in the literature.

The skin phototype was slightly more prevalent in type III than in type IV. This finding is in line with previous reports that have indicated that individuals with intermediate and darker skin phototypes are more predisposed to melasma. This increased susceptibility may be due in part to differences in melanocyte activity and response to ultraviolet exposure [4], [13]. This relationship is particularly pertinent in Middle Eastern populations, where prolonged exposure to sunlight and other environmental factors may affect the development and persistence of pigmentation.

This was an interesting finding since the malar pattern was the most common accounting for 72.5% of cases. This is contrary to many classical descriptions indicating centrofacial melasma as the most common clinical presentation. However, similar distributions have been described in regional studies suggesting that pigmentation of the lateral facial areas may be influenced by repeated sun exposure and outdoor occupational activities [6], [14]. Ethnic, geographical, and daily activity differences can also contribute to variations in the clinical distribution of melasma among populations.

Significant association was found with telangiectasia and sun exposure experienced by 85.0% of the participants (OR = 4.67; 95% CI: 1.28–16.99; p = 0.023). This finding is consistent with the well-known role of ultraviolet radiation in the development and worsening of melasma [2], [5]. But the effects of this are not restricted to the stimulation of melanocytes. Chronic exposure to ultraviolet light can cause inflammation of the skin, changes in blood vessels, activation of mast cells, and disruption of the basement membrane, and these factors may be related to the clinical and dermoscopic findings seen in this disease [2], [15]. This association of the study further supports the potential involvement of vascular changes in melasma and its classification as a photoaging-related condition rather than as an isolated disorder of melanocytes.

75.0% of participants were on topical corticosteroids. An association with telangiectasia was also noted despite the reported p-value of 0.060 (OR = 3.33; 95% CI: 1.08-10.25). Long-term or improper use of topical corticosteroids on facial skin can cause dermatological atrophy and vascular changes such as telangiectasia [16]. It is concerning that these preparations are often used by the contemporary population without the supervision of a medical professional, especially when products containing steroids are used to lighten the skin. Although the statistical findings require further validation, this finding highlights the need for adequate patient counselling and heightened awareness of the potential adverse effects of prolonged corticosteroid use.

The most common dermoscopic finding was brown globules and dots (97.5%) followed by brown background pigmentation (90.0%) and irregular pigment network (87.5%) (Table 3). These two characteristics combined indicate that the study group has a specific epidermal pigmentation pattern. Neema and Chatterjee and Kumar et al have reported irregular brown reticuloglobular structures as characteristic dermoscopic features of epidermal melasma [8], [9], [17]. From a clinical perspective, it may be of value to evaluate the predominant pigmentary pattern when choosing the treatment modality, since epidermal pigmentation is generally considered to be more responsive to topical depigmenting agents than dermal or mixed pigmentation [6].

Another significant finding was the presence of telangiectasia in 77.5% of patients. This relatively high frequency has contributed to the recent increased recognition of the vascular component of melasma. Vascular changes may contribute to the persistence of pigmentation, as suggested by previous studies showing increased dermal vascularity and increased vascular endothelial growth factor (VEGF) expression in the affected skin [15], [18]. The proposed mechanism is supported by the findings of this investigation. The identification of vascular involvement is also of clinical relevance in the choice of treatment approaches, especially in patients with pronounced vascular features. However, the possible advantages of therapies targeting these changes, such as tranexamic acid and vascular laser procedures, need an analysis of clinical evidence and the specificities of each patient [19].

Use of oral contraceptives, melasma during pregnancy, family history, and skin phototype were not statistically significantly associated with telangiectasia. Hormonal influences are known to be important factors in the development of melasma but the presence or degree of these influences may not necessarily be an indicator of their contribution [12]. Similarly, a family history may indicate an underlying predisposition, but does not directly impact the clinical or dermoscopic appearance of individual lesions. These results suggest that different risk factors may alter different aspects of the pathogenesis of melasma. However, the lack of statistically significant associations in this study should be interpreted with caution especially in light of the relatively small sample size.

The MASI scoring system and dermoscopic examination provide complementary information for the assessment of melasma. The MASI score is a clinical measure of disease severity but dermoscopy allows for a more comprehensive evaluation of pigment distribution and vascular characteristics that may not be easily appreciated on routine examination [7], [10]. Taking these findings into account can provide additional insights for the development of personalised treatment strategies, and can improve the comprehensive evaluation of patients affected by these findings. Further studies are needed to determine whether certain dermoscopic patterns are consistently correlated with the severity of the disease and the subsequent treatment outcomes.

In interpreting these findings a number of limitations should be taken into consideration. The single-center study design and the relatively small sample size may limit the generalisability of the results to a broader population. Secondly, histopathological confirmation was not done for ethical and practical reasons. Also, there is a possibility of inter-observer variability in dermoscopic assessments. Finally, the cross-sectional nature of the study design and absence of longitudinal follow-up do not allow to assess long-term prognostic outcomes and treatment responses. Therefore, large-scale multicenter prospective studies are required to confirm these observations and to clarify the relationships between clinical risk factors, dermoscopic characteristics and disease severity in melasma patients.

Conclusions

This study found that melasma is commonly observed in females of reproductive age group with Fitzpatrick skin types III and IV. The most common clinical presentation is the butterfly pattern. Common findings during dermoscopy included brown background pigmentation, irregular pigment network and brown globules and dots, indicating a predominant epidermal pigmentary pattern. Vascular changes were frequently seen in melasma and telangiectasia may be a contributing factor. Among the clinical risk factors evaluated, sun exposure was significantly associated with telangiectasia, highlighting the role of ultraviolet radiation in the development and progression of the disease. We conclude that the association of dermoscopic evaluation and MASI-based severity assessment is a critical non-invasive tool for the characterisation of melasma, which could help clinicians in the selection of therapeutic options and in the customisation of patient management.

Future Directions

Further research, using larger prospective multicentre studies, is needed to confirm the association of dermoscopic features with disease severity and treatment response in various ethnic and geographical populations. Long-term follow-up studies to assess the evolution of dermoscopic vascular patterns during treatment can also help to define the prognostic relevance of telangiectasia in melasma. Moreover, additional clinical trials comparing vascular-targeted treatment approaches including laser-based interventions and tranexamic acid could yield further evidence for the management of patients with prominent vascular

features. Besides these investigations, it is crucial to prioritise preventive measures such as education of patients about the possible adverse effects of inappropriate topical corticosteroid use and consistent photoprotection.

References

[1] A. C. Handel, L. D. B. Miot, and H. A. Miot, "Melasma: A Clinical and Epidemiological Review," *An. Bras. Dermatol.*, vol. 89, no. 5, pp. 771–782, 2014.

[2] T. Passeron and M. Picardo, "Melasma, a Photoaging Disorder," *Pigment Cell Melanoma Res.*, vol. 31, no. 4, pp. 461–465, 2018.

[3] R. Sarkar, P. Arora, and K. V. Garg, "Cosmeceuticals for Hyperpigmentation: What Is Available?," *J. Cutan. Aesthet. Surg.*, vol. 6, no. 1, pp. 4–11, 2013.

[4] O. A. Ogbechie-Godec and N. Elbuluk, "Melasma: An Up-to-Date Comprehensive Review," *Dermatol. Ther. (Heidelb).*, vol. 7, no. 3, pp. 305–318, 2017.

[5] N. C. Sathe and M. Launico, "Melasma," in *StatPearls*. Treasure Island, FL, USA: StatPearls Publishing, 2026.

[6] M. Rodrigues and A. G. Pandya, "Melasma: Clinical Diagnosis and Management Options," *Australas. J. Dermatol.*, vol. 56, no. 3, pp. 151–163, 2015.

[7] A. G. Pandya *et al.*, "Reliability Assessment and Validation of the Melasma Area and Severity Index (MASI) and a New Modified MASI Scoring Method," *J. Am. Acad. Dermatol.*, vol. 64, no. 1, pp. 78–83, 2011.

[8] S. Neema and M. Chatterjee, "Dermoscopy in Melasma," *Pigment Int.*, vol. 3, no. 1, pp. 8–13, 2016.

[9] R. Kumar, A. Das, and D. Pandhi, "Dermoscopic Features of Melasma and Their Correlation with Wood's Lamp Findings," *Indian Dermatol. Online J.*, vol. 10, no. 2, pp. 172–178, 2019.

[10] A. C. C. Espósito, G. Brianezi, N. P. de Souza, and H. A. Miot, "Exploratory Study of Individual Characteristics of Melasma in Brazilian Women," *Int. J. Dermatol.*, vol. 54, no. 8, pp. e265–e266, 2015.

[11] A. Achar and S. K. Rathi, "Melasma: A Clinico-Epidemiological Study of 312 Cases," *Indian J. Dermatol.*, vol. 56, no. 4, pp. 380–382, 2011.

[12] P. E. Grimes, "Melasma: Etiologic and Therapeutic Considerations," *Arch. Dermatol.*, vol. 131, no. 12, pp. 1453–1457, 1995.

[13] V. M. Sheth and A. G. Pandya, "Melasma: A Comprehensive Update: Part I," *J. Am. Acad. Dermatol.*, vol. 65, no. 4, pp. 689–697, 2011.

[14] C. K. Kimbrough-Green *et al.*, "Topical Retinoic Acid (Tretinoin) for Melasma in Black Patients," *Arch. Dermatol.*, vol. 130, no. 6, pp. 727–733, 1994.

[15] E. H. Kim, Y. C. Kim, E. S. Lee, and H. Y. Kang, "The Vascular Characteristics of Melasma," *J. Dermatol. Sci.*, vol. 46, no. 2, pp. 111–116, 2007.

[16] A. Coondoo, M. Phiske, S. Verma, and K. Lahiri, "Side-Effects of Topical Steroids: A Long Overdue Revisit," *Indian Dermatol. Online J.*, vol. 5, no. 4, pp. 416–425, 2014.

[17] K. Shankar *et al.*, "Evidence-Based Treatment for Melasma: Expert Opinion and a Review," *Dermatol. Ther. (Heidelb).*, vol. 4, no. 2, pp. 165–186, 2014.

[18] T. Passeron, "Melasma Pathogenesis and Influencing Factors—An Overview of the Latest Research," *J. Eur. Acad. Dermatol. Venereol.*, vol. 27, suppl. 1, pp. 5–6, 2013.

[19] D. Steiner, C. Feola, N. Bialeski, and F. A. M. Silva, "Treatment of Melasma: Review and Update. Part II," *Surg. Cosmet. Dermatol.*, vol. 1, no. 3, pp. 114–122, 2009.