AMERICAN JOURNAL OF BIOMEDICINE AND PHARMACY
https://biojournals.us/index.php/AJBP
ISSN: 2997-7177

Article

Herpes Zoster (Shingles): Molecular Pathogenesis, Immune Mechanisms, Clinical Manifestations, Therapeutic Advances, and Prevention Strategies – A Comprehensive Review

Tamara Amer Taha[*1]
1. College of Basic Education, University of Diyala, Iraq
*Correspondence: basicsci28@uodiyala.edu.iq

Citation: Taha, T. A. Herpes Zoster (Shingles): Molecular Pathogenesis, Immune Mechanisms, Clinical Manifestations, Therapeutic Advances, and Prevention Strategies – A Comprehensive Review. American Journal of Biomedicine and Pharmacy 2026, 3(10), 90-104.

Received: 30th Aug 2026
Revised: 20th Sep 2026
Accepted: 10th Oct 2026
Published: 30th Oct 2026

Copyright: © 2026 by the authors. Submitted for open access publication under the terms and conditions of the Creative Commons Attribution (CC BY) license (https://creativecommons.org/licenses/by/4.0/)

Abstract: The latent varicella-zoster virus (VZV), a member of the Herpesviridae family, reactivates to cause herpes zoster (HZ), sometimes referred to as shingles, a neurocutaneous illness. VZV creates a lifetime delay inside sensory ganglia after primary infection, which typically presents as varicella (chickenpox). When VZV-specific cellular immunity decreases, especially with aging, immunosuppression, or long-term medical problems, the virus reactivates. The clinical presentation of herpes zoster is characterised by unilateral dermatomal pain followed by a vesicular skin eruption; however, severe complications such as postherpetic neuralgia (PHN), ophthalmic involvement, neurological disorders, and disseminated infection may occur.Recent advances have improved understanding of the molecular mechanisms involved in VZV latency, immune regulation, neuroinflammation, and chronic pain development. Antiviral therapies, including acyclovir, valacyclovir, and famciclovir, remain the mainstay of treatment, particularly when initiated early. In addition, recombinant zoster vaccines have significantly improved prevention strategies, especially among older adults and immunocompromised individuals. This review summarizes current knowledge regarding VZV biology, epidemiology, pathogenesis, immune responses, clinical manifestations, diagnosis, treatment approaches, and recent preventive strategies. Understanding the complex interaction between viral persistence and host immunity is essential for improving disease management and reducing herpes zoster-associated morbidity.

Keywords: Herpes Zoster, Varicella-Zoster Virus, VZV Reactivation, Postherpetic Neuralgia, Oxidative Stress

Introduction

The widespread viral condition known as herpes zoster (HZ), or shingles, is caused by the latent varicella-zoster virus (VZV) reactivating. At different phases of infection, the highly neurotropic human herpesvirus VZV can produce two separate clinical syndromes. Varicella, also known as chickenpox, is caused by a primary infection and is usually marked by a widespread vesicular rash.[1]. The virus remains dormant among sensory neurons of the dorsal root ganglia and cranial nerve ganglia after the initial infection has resolved. Under conditions associated with impaired immune surveillance, particularly reduced VZV-specific T-cell immunity, the virus may reactivate and migrate along sensory

nerve fibers to the skin, producing the characteristic dermatomal rash and neuropathic pain associated with herpes zoster. Although the disease is often self-limited in immunocompetent individuals, it can cause significant morbidity due to persistent neuropathic pain and other complications.[2].

The global burden of herpes zoster has increased due to population aging and the growing prevalence of chronic diseases that impair immune function. Approximately one-third of individuals are estimated to develop herpes zoster during their lifetime, with the highest incidence observed among older adults and immunocompromised populations. The most clinically significant complication is postherpetic neuralgia (PHN), defined as persistent neuropathic pain following resolution of the skin lesions, which can substantially reduce quality of life.[3]

The pathogenesis of herpes zoster involves a complex interaction between viral latency mechanisms and host immune responses. Recent research has highlighted the importance of cellular immunity, inflammatory pathways, oxidative stress, and neuroimmune interactions in viral reactivation and disease progression. Furthermore, advances in recombinant vaccine technology have changed the preventive landscape of herpes zoster.

This review aims to provide an updated overview of herpes zoster, focusing on viral biology, mechanisms of latency and reactivation, immune responses, clinical characteristics, diagnostic approaches, current treatments, and emerging prevention strategies. [4,5].

Objectives

1. Screen patients for varicella susceptibility and possible sequelae, especially in high-risk populations.
2. Based on clinical appearance and diagnostic results, distinguish varicella from other vesicular or febrile rash conditions.
3. Evaluate risk factors and the severity of the illness to determine the best course of treatment.
4. In order to deliver effective, thorough, and coordinated care, effectively communicate with members of the interprofessional healthcare team regarding the risks, prevention, and treatment of varicella.
5. Get free multiple-choice questions about this subject.

Virology and Molecular Characteristics of Varicella-Zoster Virus

The varicella-zoster virus (VZV) is the infectious agent that causes chickenpox, often known as varicella. The virus causes herpes zoster, often known as shingles, which is caused by the reactivation of a latent infection, and chickenpox, which is usually a primary infection in nonimmune hosts.[6]. Heberden initially distinguished between smallpox and chickenpox in 1767. It has been suggested that the phrase "chickenpox" originates from either the Old English word "gigan," which means "to itch," or the French term for "chickpeas", chiche-poix, due to their small vesicle size. The relationship between varicella (chickenpox), and herpes zoster (shingles), was identified for the first time in 1888, when von Bokay documented that children would contract varicella through contact with an individual who suffered from chickenpox. Varicella was caused in susceptible neonates, injected with vesicle fluid taken from individuals suffering from herpes zoster, as a definitive method to confirm the link between these two diseases, was employed by Kundratitz (1922), and Bruusgaard (1932). The same virus was found in both patients, confirming that their etiologies were the same.[7]

Coughing, sneezing, and coming into contact with skin sores can all spread the airborne illness known as chickenpox. The average incubation time is roughly two weeks, and symptoms start 10 to 21 days after exposure. A skin rash caused by chickenpox appears as tiny, itchy blisters that heal over (see Image).[8]. Varicella, or chickenpox. Usually lasting five to seven days, the rash first appears on the face, back, and chest before spreading and causing fever, exhaustion, pharyngitis, and headaches. Before the rash forms, the virus may spread for one to two days until all of the sores have crusted over. Pneumonia, inflammation of the brain, and bacterial skin infections are examples of complications. Compared to youngsters, the illness is more severe in adults [9] as shown in figure 1.

Polymerase chain reaction testing of the blister fluid or scabs confirms the diagnosis of chickenpox, which is made based on the presenting symptoms. To ascertain whether immunity is present, tests for antibodies may be conducted. While varicella reinfections are possible, they are typically asymptomatic and far less severe than the initial infection. The varicella vaccine has prevented

between 70% and 90% of infections and 95% of severe disease since it was first made available in 1995, greatly reducing the number of cases and sequelae. Routine immunisation for children is recommended. Immunisation within 3 days of exposure may still improve outcomes in children.[10][11].



Figure1. Varicella-Zoster Virus (Vzv)

Classification and Genome Structure of Varicella-Zoster Virus (VZV)

The extremely neurotropic Varicella-zoster virus (VZV), also called Human herpesvirus-3 (HHV-3), is a member of the genus Varicellovirus, subfamily Alphaherpesvirinae, and family Herpesviridae. After an initial infection, VZV can create a latent infection that lasts a lifetime in host sensory neurons, just like other members of the Herpesviridae family. Because of this special biological characteristic, the virus can survive in the host and reactivate later in life, causing herpes zoster.[12].

An internal double-stranded DNA genome, an icosahedral capsid, a protein-rich tegument layer, and an exterior lipid envelope containing viral glycoproteins make up the four main structural elements of the VZV virion. More than 70 open reading frames (ORFs) are encoded by the roughly 125 kilobase pairs (kbp) of linear, double-stranded DNA that make up the VZV genome. These viral genes control vital functions including as immune evasion, host-cell entrance, viral replication, and latency maintenance [13].

Repeated sequences that support genome stability and replication surround the unique long (UL) and unique short (US) regions that make up the VZV genome. Attachment, membrane fusion, cell-to-cell transmission, and viral dissemination within host tissues are all critical functions of viral glycoproteins, especially gE, gB, gH, and gL. Among these, glycoprotein E (gE) is considered one of the most abundant and immunogenic surface proteins and represents an important target for vaccine development.[14]. Following entry into susceptible host cells, VZV utilises its genomic machinery to initiate viral replication. However, during latency, viral replication is suppressed, and the viral DNA persists as an episomal element within sensory neurons. Limited expression of latency-associated viral transcripts enables the virus to avoid complete immune elimination while maintaining the ability to reactivate when host immune surveillance declines [15]. Understanding the molecular classification and genomic Organisation of VZV is essential for explaining its pathogenic behaviour, particularly the transition from primary varicella infection to lifelong neuronal latency and subsequent herpes zoster reactivation [16] as shown in figure 2.

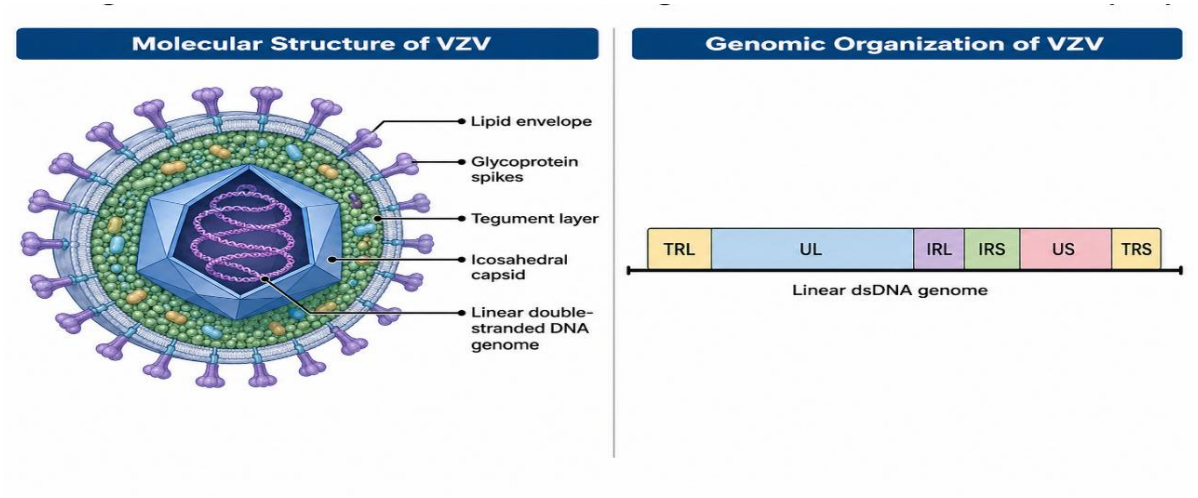

Figure 2. Molecular structure and genomic Organisation of Varicella-Zoster Virus (VZV). The virion consists of an envelope containing viral glycoproteins, a tegument layer, an icosahedral capsid, and a linear double-stranded DNA genome. The genome is organised into unique long (UL) and unique short (US) regions flanked by repeat sequences.

Viral Life Cycle

During primary infection, varicella-zoster virus (VZV) enters the host through the respiratory mucosa, where it undergoes initial replication before disseminating through lymphatic and hematogenous pathways. The virus subsequently reaches cutaneous epithelial cells, resulting in the development of the characteristic vesicular rash associated with varicella (chickenpox). During this phase, VZV can invade sensory nerve endings and migrate through retrograde axonal transport to sensory ganglia, where it establishes a persistent latent infection. [4,17]. Within sensory neurons, VZV remains dormant by limiting viral replication and maintaining its genome in an episomal state. This restricted viral activity, together with immune evasion mechanisms, enables the virus to persist within the host for life. Reactivation of latent VZV occurs mainly when VZV-specific cell-mediated immunity declines, as observed with aging, immunosuppression, or chronic diseases. Following reactivation, active viral replication in sensory neurons leads to viral transport along nerve fibers toward the skin, producing the localized dermatomal lesions and neuropathic pain characteristic of herpes zoster [18] as shown in figure 3.

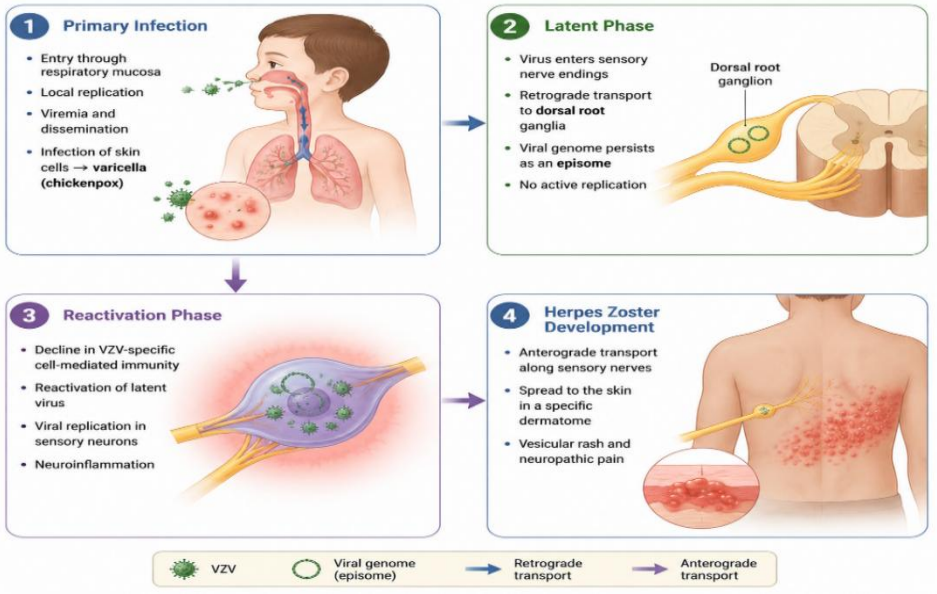

Figure 3. Life cycle of Varicella-Zoster Virus (VZV): from primary infection and establishment of neuronal latency to viral reactivation and development of herpes zoster.[10]

Establishment of Viral Latency

After the primary infection with Varicella-Zoster Virus (VZV), the virus does not completely disappear from the body. Instead, it establishes a lifelong latent infection inside the sensory nerve ganglia, mainly the dorsal root ganglia and sometimes cranial nerve ganglia such as the trigeminal ganglia. During this stage, the virus remains inactive or dormant without producing new infectious viral particles.[19]. The establishment of latency begins after VZV replicates during the primary infection and spreads to the skin. From the infected skin lesions, the virus can enter sensory nerve endings and move backwards along the nerve fibres toward the sensory ganglia. Once inside neuronal cells, the viral genome persists in the nucleus in a silent or low-activity state.[20]

During latency, VZV gene expression is highly restricted compared with active infection. This limited viral activity helps the virus avoid immune clearance while remaining inside the host for many years. The immune system, especially cell-mediated immunity, plays an important role in keeping the virus under control and preventing reactivation. [9,21]. When immunity declines due to ageing, immunosuppression, chronic disease, or severe stress, latent VZV may reactivate. The virus then replicates again inside sensory neurons and travels along the nerve toward the skin, producing the painful dermatomal rash known as herpes zoster or shingles.[6].

Epidemiology

98% of adults worldwide are seropositive for VZV. Every year, varicella causes roughly 7000 deaths worldwide. Winter and spring are when most cases happen. Over 9000 hospital admissions in the US are caused by VZV each year, with the age group of 4 to 10 years old having the highest prevalence. [21].

The overall incidence of varicella has decreased by about 85% since the varicella vaccine was introduced in 1995, indicating herd immunity. A second booster of the varicella vaccine was added to the usual immunization schedule for children as a result of increased numbers of breakthrough cases of varicella among vaccinated children in the older age groups. The peak age of occurrence of varicella changed from 5-9 years to 10-14 years.[7] Before the varicella vaccine was developed, 90% of children in the US had the illness by the time they were ten years old. Varicella is usually symptomatic.[8]. About 20% of healthy adults and 50% of immunocompromised people get herpes zoster, which is a marker of latent VZV virus reactivation [9]. The latter group has significant morbidity and death. Compared to main instances, secondary cases among household contacts typically have more severe disease. Varicella typically affects older adults in the tropics and can result in more serious illness. Recently, a case involving an 81-year-old patient was reported [10][11].

Pathophysiology

Like all herpesviruses, the causal agent, VZV, is a deoxyribonucleic acid virus that is a member of the human herpesvirus subfamily Alphaherpesvirinae. The virus enters the respiratory system through the conjunctival or upper respiratory mucosa and settles in the upper respiratory tract. Within two to four days, the virus replicates in local lymph nodes. Four to six days later, primary viremia spreads the virus to reticuloendothelial cells in the liver, spleen, and other organs.[22] The typical rash is due to secondary viremia with the viral replication in the skin and other organs. Secondary viremia also facilitates the transport of the virus into the lungs and airways allowing further transmission. This is the time when the patient's CNS can be affected (encephalitis), their liver can be affected (hepatitis) as well as they develop an infection in their lungs (pneumonia) [12].

Both humoral and cell-mediated immune responses can be influenced by varicella. These reactions produce long-lasting immunity. Recurrent subclinical infections are possible, but subsequent chickenpox episodes are extremely rare in immunocompetent people. The immunity acquired during a chickenpox episode may be strengthened by preexposure and subclinical infections. [23].Host IgG, IgM, and IgA are produced as a result of exposure. IgG antibodies provide immunity and last a lifetime. In order to reduce the length of the initial varicella infection, cell-mediated immune responses are crucial. It is hypothesized that varicella travels from mucosal and epidermal sores to local sensory nerves during primary infection, where it remains dormant in the sensory nerves' dorsal ganglion cells.

The virus is restrained by the immune system. But later in life, reactivation can still happen, leading to the clinically unique herpes zoster syndrome (shingles) [13].

Histopathology

The histological characteristics of herpes simplex, varicella, and herpes zoster infections are identical. Intraepidermal vesicles frequently show multinucleated large cells, which arise from the fusion of infected keratinocytes, together with ballooning degeneration of keratinocytes. Acantholysis, in which individual keratinocytes split off and float freely inside the blister area, is a defining feature.[24] These separated cells frequently exhibit characteristic viral alterations, such as inclusion bodies inside the nuclei, numerous nuclei, and chromatin clumping at the nuclear margins. To differentiate these viral infections, clinical correlation, immunohistochemistry, and viral culture or polymerase chain reaction are required [14].

History and Physical

A rash, oral sores, malaise, and a low-grade fever follow the prodromal symptoms in adults and adolescents, which include headache, nausea, decreased appetite, and aching muscles. The cutaneous rash may be preceded by oral symptoms. In youngsters, oral cavity lesions or a rash may be the first indication of the illness, and prodromal symptoms may not be present. The itchy, erythematous macules and papules that appear initially on the scalp and face are soon spread to the trunk and limbs. [25]. About 12 hours after the onset of symptoms, the lesions begin to develop into 1 to 3 mm in size transparent vesicles with red halos (like dew drops on a rose petal). "The number of vesicles, which often include the oral mucosa, varies from a few to several hundred. It is typical to spare the lower and distal extremities. Each lesion heals in 7 to 10 days, and older vesicles turn into pustules and crusts. Varicella is characterized by the presence of lesions at every stage of development (see Image. Varicella Rash). [26]. Itching is quite severe at the time of blister formation. Blisters can occur on many parts of your body including vagina, palms and soles. Tiny, itchy, painful ulcers will be seen in the tonsils and mouth (enanthema) prior to or concurrent with the skin rashes. Enanthema appears in adults one to three days prior to the onset of the cutaneous eruption. Pneumonia is the most serious complication in adults. In addition, adults will have a wider range of skin lesions and will have an elevated temperature for a greater duration. The individual that has contracted the disease is contagious from one to two days prior to when they become symptomatic due to the presence of live virus in their nasal secretions that appears one to two days prior to the exanthematous rash [27].

The main diseases caused by the Varicella-Zoster Virus (VZV)

Varicella-Zoster Virus – VZV (Chickenpox)

The varicella-zoster virus, which also causes herpes zoster (shingles) when reactivated, is the highly contagious disease that causes chickenpox, often known as varicella. A skin rash with tiny, stinging blisters that gradually scab over is how the illness first appears Although Varicella is primarily an infection of childhood, however, it represents a greater risk to adolescents, adults, pregnant women, newborns and individuals who are immunocompromised. Antiviral treatment or supportive care with the use of Varicella Zoster Immune Globulin often is necessary in these cases.[19]. Although laboratory studies may confirm instances or reveal problems, the diagnosis is usually clinical. Varicella can be effectively prevented by vaccination using 1- or 2-dose regimens, Many countries have now instituted Universal Pediatric Immunization Programs. Because this is such a rapidly spreading disease, both prevention (e.g., through immunizations) and rapid treatment of those at greatest risk are important.[17].

Medical professionals will be provided with a comprehensive overview of epidemiology, clinical presentations, diagnostic procedures and evidence-based treatments to treat mild and severe types of varicella in this course. Along with new preventative strategies that emphasize immunization, participants learn about current treatment techniques, such as the use of antivirals and supportive medicines.[28]. The course emphasizes the value of interprofessional cooperation by showing how clinicians—including doctors, nurses, pharmacists, and public health specialists—can improve patient outcomes through coordinated efforts. Interprofessional teams guarantee prompt diagnosis,

customized treatments, and strong preventative initiatives, especially for high-risk groups, by promoting effective communication and role clarity. This lowers complications and enhances the quality of care for a variety of patient populations.



Figure 4. Varicella-Zoster Virus – VZV Causes (Chickenpox) [22]

Varicella, commonly known as chicken pox, is caused by Varicella zoster virus (VZV), which is a herpes virus that has a global presence. Most herpes viruses enter into a latent state upon completion of the primary infection. However, VZV does.[4] The chicken pox virus is inhaled through respiratory transmission via aerosols containing infectious droplets. As such, it is extremely transmissible and will readily spread. Once infected, the first site for the chicken pox virus is at the mucosal surfaces of the upper respiratory tract. The chicken pox virus enters systemic circulation within 2 to 6 days post-infection, another period of viremia ensues approximately 10-12 days post-infection. It is during this second episode of viremia that the chicken pox lesions begin to erupt. In addition to IgA, IgM, and IgG antibodies being generated against varicella, the IgG antibody confers long-term immunity. Following an individual's first exposure to varicella, the virus becomes localized to the sensory nerve cells and can potentially become reactivated as shingles[29].

Varicella-Zoster Virus – VZV (Shingles)

The varicella-zoster virus (VZV) reactivates to cause shingles, also known medically as herpes zoster. The virus that causes chickenpox is the same one. The virus does not entirely exit the body after chickenpox, instead, it lies dormant in the nerve ganglia for many years. The virus may reactivate when the immune system deteriorates, as well as with aging or exposure to specific conditions. It then travels along the nerve to the skin, where it causes discomfort and a rash.[The rash is known as "shingles" because it frequently manifests as a painful band or belt on one side of the body, particularly the belly, back, or chest. But it can also show up on the limbs, eyes, ears, scalp, or face.

After the initial VZV infection, shingles develops and frequently manifests as chickenpox. The virus stays dormant in the nerves after healing, especially in the sensory nerve ganglia. The immune system normally keeps the virus dormant. However, the virus may recur if immunity declines. Following reactivation, the virus uses nerve fibers to go from the nerve ganglia to the skin. As a result, symptoms manifest in a dermatome—a region of skin supplied by a specific nerve. This explains why the rash typically only affects one side of the body and does not cross the midline.

There is no single direct cause of viral reactivation, but several factors increase the likelihood of developing the disease. The most significant is advancing age, especially after 50, because cellular immunity against the virus gradually weakens. The risk is also higher in people with diabetes, cancer, kidney disease, autoimmune diseases, or those using immunosuppressant drugs such as corticosteroids for extended periods, chemotherapy, or post-organ transplant medications. Severe stress, lack of sleep, malnutrition, acute illnesses, or psychological stress can also contribute to weakened immunity, but these alone are not sufficient causes in everyone. A person with shingles can transmit the VZV virus to someone who has never had chickenpox and has not been vaccinated against it. However, the person in contact does not immediately develop shingles, they may develop chickenpox first. Infection often occurs through contact with the fluid from the blisters, so the disease is contagious from the time the blisters appear until they dry and scab over. After the scabs dry, the risk of infection decreases significantly. To reduce the risk of infection, the rash should be covered, the blisters should not be touched or scratched, hands should be washed thoroughly, and contact with unvaccinated pregnant women, newborns, and immunocompromised individuals should be avoided until the blisters have dried.5. Causes of Shingles

The reason for shingles is primarily caused by the Varicella-Zoster Virus (VZV) which is also responsible for causing chickenpox. When you contract chickenpox your rashes will heal but the VZV does not disappear as well. Instead the VZV resides in an inactive state in nerve ganglia near to the spinal column or sensory nerves. At some point many years after contracting chicken pox, the VZV can become active again. The cause of this condition is when the previously dormant chicken pox virus becomes activated again inside of the body's nerves.

Factors that contribute to reactivation include: - Weakened immunity, whether due to ageing, chronic diseases, immunosuppressant medications, or chemotherapy.

1. Advancing age, especially after 50, because the immune system's ability to keep the virus dormant gradually declines. The World Health Organisation states that the risk of shingles increases with age due to weakened immunity against the virus.
2. Chronic diseases such as diabetes, kidney disease, cancer, or autoimmune disorders.
3. Severe stress, fatigue, and lack of sleep, as these can weaken the body's ability to fight the virus, but they are not the only cause. - Immunosuppressant medications such as corticosteroids for extended periods, organ transplant medications, and some biological or chemotherapy treatments.
4. A previous chickenpox infection, because a person will only develop shingles if the VZV virus is already present in their body, often after chickenpox or previous exposure to the virus.
5. In short: Shingles is not caused by cold, heat, or any particular food, but rather by the reactivation of an old virus within the nerves when the immune system is less able to control it.



Figure 5. Varicella-Zoster Virus – VZV Causes (Shingles)

The virus can also cause or be associated with several serious complications, including:

1. Postherpetic neuralgia, a nerve pain that persists after the rash has disappeared and may last for months or longer. It is one of the most common complications of shingles.
2. Ophthalmic herpes zoster, which occurs when the virus infects a nerve branch near the eye. It can cause pain, redness, and visual complications if not treated promptly.
3. Encephalitis or meningitis, which occurs rarely, especially in immunocompromised individuals.

4. Pneumonia, which can occur as a complication of chickenpox or shingles, especially in adults or immunocompromised individuals. The CDC notes that complications of shingles can include hearing or vision loss, encephalitis, and pneumonia.
5. Secondary bacterial skin infections, which occur when the blisters are scratched or become contaminated, leading to skin inflammation.

Risk factors for severe varicella in adolescents and adults are as follows:

1. Steroid therapy: administering prednisolone at levels of 1 to 2 mg/kg/d for two weeks or more is a considerable risk factor for serious illness. Even short-term use of these dosages just before or during the varicella incubation period might cause severe or lethal varicella.[5]
2. Immunocompromised situations include cancer, antineoplastic drugs, HIV, and other acquired or congenital immunodeficiency illnesses. It is believed that those with cellular immunodeficiency are more susceptible to severe varicella than those with humoral immunodeficiency.
3. Pregnant women are more likely to contract severe varicella, especially pneumonia. Furthermore, transplacental transmission of maternal varicella and viremia to the fetus is possible. Newborn varicella is the result of this. The risk of a serious disease is highest in infants born between five days prior to and two days following the mother's varicella rash.[6] A newborn is more susceptible to severe varicella during the first month of life if the mother is seronegative. A newborn is at risk if they are delivered before 28 weeks of gestation since transplacental transmission of IgG antibodies takes place beyond this time.

Evaluation

Symptoms and signs provide the primary basis for establishing a diagnosis of varicella. Methods for confirming include examining the contents of blisters using scrapings from uncrusting lesions and analyzing blood for evidence of an acute immunological response. Polymerase Chain Reaction (PCR) is currently the most reliable method for confirmation. This can be performed on non-skin samples such as cerebrospinal fluid and bronchoalveolar lavage. Direct Fluorescent Antibody Testing has largely replaced the Tzanck Test. Cultivation of the Vesicular Fluid can also be done but the yield will be lower than with PCR. Blood tests can detect Acute Infection (IgM), Prior Infection (IgG) and Subsequent Immunity (IgG). Fetal Varicella in Pregnancy is confirmed via ultrasound, although It is suggested that this should take place at least Five Weeks post Maternal Onset. The amniotic fluid can undergo a PCR (deoxyribonucleic acid) test. However, there is a greater chance of spontaneous abortion following amniocentesis than there is of fetal varicella.[15][16].

Treatment / Management

Those with the disease usually have to stay home while they are sick because of the risk of spreading it. In addition, using gloves and cutting fingernails will assist in preventing itching from scratch or infection which is a secondary condition that could develop due to this itch.[17][18] Calamine lotion is used for treatment of pruritus. It also aids in washing off bacteria through warm water use each day.[19]

Children: The treatment of symptomatic relief. If administered within 24 hours of the appearance of a rash, it shortens the duration of symptoms by 1 day. However, it does not have an impact on the risk of complications or is recommended to be used in individuals who have healthy immune systems.

"Adults": Antiviral drugs (valacyclovir or acyclovir), are generally recommended for children who have been treated for the initial 24 to 48 hours of the rash, since children tend to experience a worse case. Studies have demonstrated that acyclovir significantly reduces both the length of time and the severity of varicella when administered between 24 and 72 hours of the appearance of the skin lesions. Antiviral treatments are also frequently recommended for adults, especially pregnant women, based on an increase in complications associated with pregnancy. Oral medication will likely always be considered first line therapy, however, patients who are immunocompromised and/or being treated with chronic systemic corticosteroids may benefit from IV antiviral medications due to an elevated risk of developing serious disease and its consequences. Management should be treated with supportive

care (i.e., hydration and anti-pyretic/anti-histaminic medications). Non-immune immunocompromised individuals, pregnant females and at-risk neonates are recommended to receive an intramuscular dose of Varicella Zoster Immune Globulin (VZIG) (125 units/kg body weight, max 625 units) in order to act as a passive form of prevention if they have been exposed to varicella within 96 hrs. The duration of immunity from varicella infection lasts approximately three weeks. For patients listed above with lower levels of specific anti-varicella antibodies (and therefore less likely to provide adequate protection against re-infection), intravenous immunoglobulin (>or = 400 mg/kg), which contains larger amounts of varicella-specific IgG, can be used for post-exposure varicella prevention. Oral Acyclovir administered for one week in the usual varicella dosing schedule (within 7-10 days post exposure) is another preventive option. Post-exposure varicella vaccination (administered within 72-120 hours) may also either prevent or reduce the severity of varicella in healthy, immune competent non-immunized persons greater than twelve months of age who are otherwise qualified to receive this live attenuated vaccine[20].

Differential Diagnosis

Although the three dermatological conditions—monkeypox, smallpox, and chickenpox—can be distinguished by their distinct symptoms, they are occasionally confounded due to similar presentations including fever, rash, myalgia, chills, and headache. Even though different rash-inducing disorders have different skin lesions, diagnostic testing can help differentiate between them. The pattern of skin rash symptoms is typically used to make the clinical diagnosis of monkeypox infection. While monkeypox lesions remain consistently at the same stage and progress at the same rate, varicella lesions can be observed concurrently at multiple stages, including macular, papular, vesicular, pustular, and crusted forms [21].

The similar looks of chickenpox and monkeypox can often make diagnosis difficult.[22] Coinfections have been reported, mostly in Central Africa.[23] Another sign of smallpox is a widespread vesicular eruption, which is no longer a normal occurrence. Vesicular viral exanthems "such as those caused by coxsackieviruses", varicella (chickenpox) can be ruled out by a number of conditions such as, bullous insect bite reaction, drug eruption, pityriasis lichenoides et varioliformis acuta, rickettsial pox, scabies and widespread herpes simplex virus infection. The outlook is excellent for children in good general health. However, in immunocompromised people, the illness has a significant morbidity rate. Although most varicella infections offer lifetime protection, cases of clinical reinfection in healthy children have been documented[24].

Complications

In youngsters, chickenpox is usually a light infection, almost all of them recover without any problems. Adolescents and adults usually have more severe varicella than children, with more skin lesions. Adults, immunocompromised people, and pregnant women may experience the following serious complications:

A subsequent bacterial infection is a frequent consequence that can cause scarring and manifest as cellulitis, impetigo, or erysipelas. Scars become deeper and more noticeable in adults. Untreated varicella pneumonia carries a mortality risk of 10% to 30%.

A person's lifetime risk of contracting zoster is 20% if they have already had varicella. Herpes zoster, chicken pox, and facial nerve palsy were documented to occur together in an immunocompetent patient [25].

Guillain-Barré syndrome, encephalitis, and acute cerebellar ataxia are among the rare (<1 per 1000) central nervous system effects. A stroke may arise from varicella zoster's damage to the head and neck arteries.[13] Because children with varicella avoid taking aspirin, Reye syndrome, which is characterized by encephalitis and fatty liver, has become uncommon [4].

Congenital varicella syndrome (varicella embryopathy) is associated with a 2% incidence of maternal varicella during the first 20 weeks of pregnancy. Low birth weight, cutaneous scarring, visual abnormalities, cerebral atrophy, psychomotor delay, and hypoplastic limbs are examples of potential congenital defects [12]. It is possible for children whose moms had varicella during pregnancy to

develop zoster at a young age without ever having extrauterine varicella. Maternal varicella that appears between five days prior to and two days after delivery may result in severe neonatal varicella, which is defined by the lack of maternal antibody protection. Conversely, there is minimal risk of congenital varicella syndrome or newborn problems from maternal herpes zoster, most likely due to circulating maternal antibodies [7].

In immunocompromised people, varicella can cause major problems and even death. These people frequently have a more extensive and peculiar cutaneous eruption, which can occasionally be accompanied by purpuric or hemorrhagic lesions. The central nervous system, liver, and lungs are the main organs affected. Among these are some very rare complications such as thrombocytopenia, hepatitis, glomerulonephritis, optic neuritis, keratitis, arthritis, myocarditis, pancreatitis, orchitis and vasculitis [15].

Deterrence and Patient Education

Morbidity from chickenpox can be decreased by education. To avoid bacterial infections and skin damage, parents of infected children should trim their fingernails. Additionally, parents should be cautioned against giving aspirin to young children in order to manage fever and prevent Reye syndrome. To prevent dryness and irritation, patients should apply moisturizers and cold compresses [27].

In order to reduce infectious morbidity, all professionals should advise parents to vaccinate their children. During a physical examination, pediatric varicella patients typically exhibit fever and rash. A comprehensive assessment may reveal a serious bacterial superinfection or possible neurological or pulmonary issues. To prevent herpes zoster, the US Advisory Committee on Immunization Practices recommends vaccination for all individuals over 60. If they had chickenpox as children, one in five adults—especially those with weakened immune systems—get shingles. "Adults over 60 who were diagnosed with chickenpox before the age of one are most likely to develop shingles". Through blister contact, shingles patients can infect non-immune people with chickenpox [13].

Pearls and Other Issues

Immunocompetent children with varicella can be treated symptomatically with tepid baths, antihistamines, calamine lotion, and antipyretics (such as acetaminophen). Early antiviral treatment can lessen or completely eliminate serious VZV infection-related consequences. These anti-viral drugs are typically indicated to be used in health adults and teens, as well as in kids who have chronic lung disease or skin disease and/or receive intermittent oral steroids, inhalant steroids, or salicylates (such as aspirin) on an ongoing basis. Nonetheless, since varicella has limited potential of being treated due to its generally self-limited nature, there is no recommendation for routine use of these drugs in otherwise healthy young people [28].

1. Pregnant women are more susceptible to chickenpox than adults, and the unborn child is at risk for congenital varicella syndrome, perhaps severe varicella, and herpes zoster. Anti-VZV immunoglobulins ("0.5 to 1 ml/kg IV") must be administered within 10 days of VZV exposure in nonimmunized pregnant women. Anti-VZV immunoglobulins must be given to the infant as soon as possible, no later than 10 days after birth, because severe neonatal chickenpox may ensue from maternal chickenpox that occurs within 7 days before or after delivery. For babies born before 28 weeks of amenorrhea or weighing less than 1000 grams at birth, the period should be extended to 21 days prior to delivery [29].
2. The live attenuated VZV vaccine (Oka strain), which was approved by the US Food and Drug Administration in 1995, has impressive performance, with seroprotection rates of at least 99% after two doses and about 85% after a single dose in healthy juvenile populations.[24] To improve protection and slow the deterioration of vaccine-induced immunity, two vaccination doses are recommended, usually given at 12 to 15 months and 4 to 6 years. Pregnancy and people with immunosuppression due to hematologic malignancies, HIV infection ("if cluster of differentiation 4+ T cell levels are <15% or <200 cells/mcL"), "other T cell immunodeficiencies or systemic

immunosuppressive therapies such as tumor necrosis factor inhibitors or prednisone" ("≥20 mg daily for ≥2 weeks or ≥2 mg/kg daily for people under 10 kg") [30].

Enhancing Healthcare Team Outcomes

Inhaling aerosolized droplets from an infected person is often how chickenpox is contracted. Children under the age of ten account for the majority of instances. The majority of kids who get chickenpox have great outcomes. However, morbidity and death are higher among immunocompromised people [31].

A coordinated, patient-centered approach involving doctors, advanced clinicians, nurses, pharmacists, and other healthcare workers is necessary to effectively manage varicella (such as chickenpox). Accurately diagnosing varicella, evaluating for complications, and creating customized care plans that include antiviral therapy and advice on isolation and immunization are all tasks for doctors and advanced clinicians.[15] Nurses play a critical role in providing supportive care, monitoring symptoms, and educating patients and their families about infection management. Pharmacists help by making sure antiviral drugs are used safely, offering vaccine advice, and encouraging medication compliance. During outbreaks, public health experts and infection control teams play a crucial role in supporting surveillance, contact tracing, and immunization initiatives. By identifying infectious cases early and enforcing infection control procedures, clinicians limit healthcare-associated spread [32].

The interprofessional team is in charge of education, which is essential to reducing chickenpox morbidity. Parents of children with this condition can also protect against skin damage and/or secondary infection by cutting their child's fingernails. In addition, because of the risk of developing Reye syndrome, parents of these children should be cautioned not to give their children aspirin for fever. To avoid dryness and itching, patients should be instructed to moisturize their skin and apply cold compresses. [33] Since the vaccine is safe and very efficient, all medical professionals should encourage parents to vaccinate their children in order to prevent the morbidity linked to the infection. For additional care, children with weakened immune systems should be sent to an infectious disease specialist. Additionally, doctors should advise expectant mothers who are seronegative for chickenpox to stay away from patients who are infected. Every pregnant woman who has chickenpox needs to be treated by a group of experts who can work together to determine the best course of action [34].

When treating varicella infection consequences, the interprofessional healthcare team also improves patient care and results. To guarantee a well-coordinated response, advanced doctors, nurses, pharmacists, and other allied healthcare professionals work together effortlessly [11]. Open communication and making informed joint decisions about the illness or disease in collaboration with patients/families will support building and maintaining a relationship that is built upon trust. As such, healthcare teams will be able to provide the best possible care to varicella (chickenpox) patients when they use a combination of their clinical skills, professional ethics, effective communication techniques, and coordinated teamwork. In this way, healthcare teams are providing a comprehensive and team-oriented model of care, which can lead to improved outcomes, fewer hospitalizations, and an enhanced ability to protect patient safety and public health [35].

Conclusion

Herpes zoster is a viral disease caused by the reactivation of the varicella-zoster virus (VZV), which remains latent in sensory ganglia following primary infection. Reactivation is commonly associated with declining cellular immunity due to aging, immunosuppression, and chronic diseases. Its clinical manifestations include painful dermatomal rashes and potentially serious complications, particularly postherpetic neuralgia, ophthalmic involvement, and neurological disorders. Early and accurate diagnosis is essential to distinguish herpes zoster from other conditions with similar clinical presentations and to facilitate appropriate treatment. Antiviral medications, including acyclovir, valacyclovir, and famciclovir, are most effective when initiated early, while supportive care helps alleviate symptoms. Furthermore, vaccination, preventive education, and coordinated healthcare services play important roles in reducing disease incidence, preventing complications, and improving patient outcomes, especially among older adults and immunocompromised individuals. A

comprehensive understanding of VZV latency, reactivation mechanisms, and host immune responses is therefore essential for strengthening herpes zoster prevention and management strategies.

REFERENCES

[1] T. C. Heineman, A. Cunningham, and M. Levin, "Understanding the immunology of Shingrix, a recombinant glycoprotein E adjuvanted herpes zoster vaccine," *Current Opinion in Immunology*, vol. 59, pp. 42–48, Aug. 2019.

[2] D. Watanabe, "Cutaneous herpesvirus infection," *Brain and Nerve*, vol. 71, no. 4, pp. 302–308, Apr. 2019.

[3] Y. H. Yu, Y. Lin, and P. J. Sun, "Segmental zoster abdominal paresis mimicking an abdominal hernia: A case report and literature review," *Medicine*, vol. 98, no. 15, Art. no. e15037, Apr. 2019.

[4] H. Senderovich, J. Grewal, and M. Mujtaba, "Herpes zoster vaccination efficacy in the long-term care facility population: A qualitative systematic review," *Current Medical Research and Opinion*, vol. 35, no. 8, pp. 1451–1462, Aug. 2019.

[5] C. Warren-Gash *et al*., "Human herpesvirus infections and dementia or mild cognitive impairment: A systematic review and meta-analysis," *Scientific Reports*, vol. 9, no. 1, Art. no. 4743, Mar. 18, 2019.

[6] A. R. Davis and J. Sheppard, "Herpes zoster ophthalmicus review and prevention," *Eye & Contact Lens*, vol. 45, no. 5, pp. 286–291, Sep. 2019.

[7] E. Baumrin *et al*., "A systematic review of herpes zoster incidence and consensus recommendations on vaccination in adult patients on systemic therapy for psoriasis or psoriatic arthritis: From the Medical Board of the National Psoriasis Foundation," *Journal of the American Academy of Dermatology*, vol. 81, no. 1, pp. 102–110, Jul. 2019.

[8] L. W. Miles, N. Williams, K. E. Luthy, and L. Eden, "Adult vaccination rates in the mentally ill population: An outpatient improvement project," *Journal of the American Psychiatric Nurses Association*, vol. 26, no. 2, pp. 172–180, Mar.–Apr. 2020.

[9] B. V. Rooney, B. E. Crucian, D. L. Pierson, M. L. Laudenslager, and S. K. Mehta, "Herpes virus reactivation in astronauts during spaceflight and its application on Earth," *Frontiers in Microbiology*, vol. 10, Art. no. 16, 2019.

[10] L. P. Hurley *et al*., "Primary care physicians' experience with zoster vaccine live (ZVL) and awareness and attitudes regarding the new recombinant zoster vaccine (RZV)," *Vaccine*, vol. 36, no. 48, pp. 7408–7414, Nov. 19, 2018.

[11] Y. Y. Syed, "Recombinant zoster vaccine (Shingrix®): A review in herpes zoster," *Drugs & Aging*, vol. 35, no. 12, pp. 1031–1040, Dec. 2018.

[12] C. M. Mospan and N. Colvin, "What are the new vaccination recommendations for herpes zoster?" *JAAPA*, vol. 31, no. 10, pp. 14–15, Oct. 2018.

[13] K. L. Hawkins *et al*., "Herpes zoster and herpes zoster vaccine rates among adults living with and without HIV in the Veterans Aging Cohort Study," *Journal of Acquired Immune Deficiency Syndromes*, vol. 79, no. 4, pp. 527–533, Dec. 1, 2018.

[14] H. Liu *et al*., "Research progress on varicella-zoster virus vaccines," *Vaccines*, vol. 13, Art. no. 730, 2025.

[15] W. Gao, D. Gao, L. Li, *et al*., "Bibliometric analysis and visualization mapping of herpes zoster vaccine publications from 1999 to 2024," *Frontiers in Medicine*, vol. 12, Art. no. 1516450, 2025.

[16] J. Chen, P. E. Abrahamson, Y. Ke, *et al*., "A systematic literature review of the epidemiology and burden of herpes zoster in selected locales in Asia Pacific," *Human Vaccines & Immunotherapeutics*, vol. 20, no. 1, Art. no. 2344983, 2024.

[17] Y. L. Lin, S. I. Wang, and J. C. Wei, "Effectiveness of recombinant zoster vaccine in reducing herpes zoster incidence and all-cause mortality among patients with rheumatoid arthritis: A retrospective cohort study of 21,046 individuals from TriNetX U.S. Collaborative Network," *eClinicalMedicine*, vol. 85, Art. no. 103319, 2025.

[18] C. X. Pan, M. S. Lee, and V. E. Nambudiri, "Global herpes zoster incidence, burden of disease, and vaccine availability: A narrative review," *Therapeutic Advances in Vaccines and Immunotherapy*, vol. 10, Art. no. 25151355221084535, 2022.

[19] J. Breuer, "Molecular genetic insights into varicella zoster virus (VZV), the vOka vaccine strain, and the pathogenesis of latency and reactivation," *Journal of Infectious Diseases*, vol. 218, suppl. 2, pp. S75–S80, 2018.

[20] W. J. D. Ouwendijk, D. P. Depledge, L. Rajbhandari, *et al*., "Varicella-zoster virus VLT-ORF63 fusion transcript induces broad viral gene expression during reactivation from neuronal latency," *Nature Communications*, vol. 11, no. 1, Art. no. 6324, 2020.

[21] J. Hertzog, W. Zhou, G. Fowler, *et al*., "Varicella-zoster virus ORF9 is an antagonist of the DNA sensor cGAS," *The EMBO Journal*, vol. 41, no. 14, Art. no. e109217, 2022.

[22] X. Che, S. L. Oliver, M. Reichelt, *et al*., "ORF11 protein interacts with the ORF9 essential tegument protein in varicella-zoster virus infection," *Journal of Virology*, vol. 87, no. 9, pp. 5106–5117, 2013.

[23] V. Girault, A. Stukalov, M. E. Carter-Timofte, *et al*., "Multi-proteomic profiling of the varicella-zoster virus–host interface reveals host susceptibilities to severe infection," *Nature Microbiology*, vol. 10, no. 8, pp. 2048–2072, 2025.

[24] D. P. Depledge, T. Sadaoka, and W. J. D. Ouwendijk, "Molecular aspects of varicella-zoster virus latency," *Viruses*, vol. 10, no. 7, 2018.

[25] H. Liu *et al*., "Research progress on varicella-zoster virus vaccines," *Vaccines*, vol. 13, Art. no. 730, 2025.

[26] W. Gao, D. Gao, L. Li, *et al*., "Bibliometric analysis and visualization mapping of herpes zoster vaccine publications from 1999 to 2024," *Frontiers in Medicine*, vol. 12, Art. no. 1516450, 2025.

[27] J. Chen, P. E. Abrahamson, Y. Ke, *et al*., "A systematic literature review of the epidemiology and burden of herpes zoster in selected locales in Asia Pacific," *Human Vaccines & Immunotherapeutics*, vol. 20, no. 1, Art. no. 2344983, 2024.

[28] Y. L. Lin, S. I. Wang, and J. C. Wei, "Effectiveness of recombinant zoster vaccine in reducing herpes zoster incidence and all-cause mortality among patients with rheumatoid arthritis: A retrospective cohort study of 21,046 individuals from TriNetX U.S. Collaborative Network," *eClinicalMedicine*, vol. 85, Art. no. 103319, 2025.

[29] C. X. Pan, M. S. Lee, and V. E. Nambudiri, "Global herpes zoster incidence, burden of disease, and vaccine availability: A narrative review," *Therapeutic Advances in Vaccines and Immunotherapy*, vol. 10, Art. no. 25151355221084535, 2022.

[30] J. Breuer, "Molecular genetic insights into varicella zoster virus (VZV), the vOka vaccine strain, and the pathogenesis of latency and reactivation," *Journal of Infectious Diseases*, vol. 218, suppl. 2, pp. S75–S80, 2018.

[31] W. J. D. Ouwendijk, D. P. Depledge, L. Rajbhandari, *et al*., "Varicella-zoster virus VLT-ORF63 fusion transcript induces broad viral gene expression during reactivation from neuronal latency," *Nature Communications*, vol. 11, no. 1, Art. no. 6324, 2020.

[32] J. Hertzog, W. Zhou, G. Fowler, *et al*., "Varicella-zoster virus ORF9 is an antagonist of the DNA sensor cGAS," *The EMBO Journal*, vol. 41, no. 14, Art. no. e109217, 2022.

[33] X. Che, S. L. Oliver, M. Reichelt, *et al*., "ORF11 protein interacts with the ORF9 essential tegument protein in varicella-zoster virus infection," *Journal of Virology*, vol. 87, no. 9, pp. 5106–5117, 2013.

[34] V. Girault, A. Stukalov, M. E. Carter-Timofte, *et al*., "Multi-proteomic profiling of the varicella-zoster virus–host interface reveals host susceptibilities to severe infection," *Nature Microbiology*, vol. 10, no. 8, pp. 2048–2072, 2025.

[35] D. P. Depledge, T. Sadaoka, and W. J. D. Ouwendijk, "Molecular aspects of varicella-zoster virus latency," *Viruses*, vol. 10, no. 7, 2018.